

Opinion

Direct Percutaneous Endoscopic Jejunostomy in Patients with Altered Anatomy

Taylan Kav MD¹

Cite this article as: Kav T. Direct Percutaneous Endoscopic Jejunostomy in Patients with Altered Anatomy. *Arch Iran Med.* 2012; **15**(3): 176.

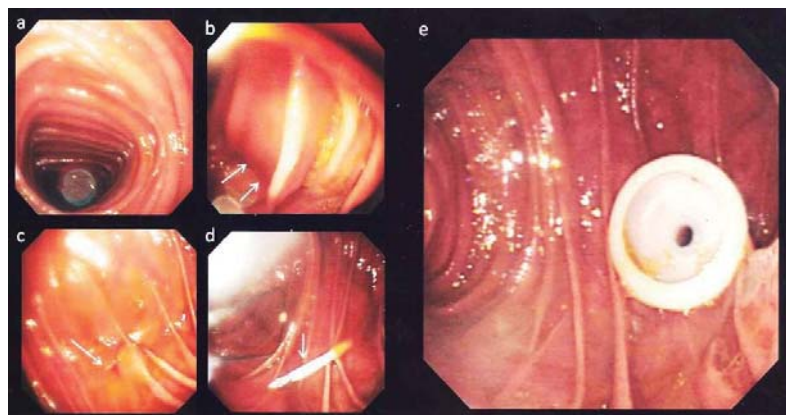


Figure 1 a) Normal jejunal efferent loop 10 cm distal to the anastomosis site, where transillumination and, b) finger indentation (arrows) are clearly seen. c) Arrow shows the tip of the needle used for anesthesia infiltration. d) Arrow shows the introducer. Note the open snare at the left hand side. e) Completed procedure and bumper visualized.

Long-term enteral feeding is vital in the management of conditions such as cerebrovascular disease or dementia. Placement of a percutaneous gastrostomy (PEG) tube is the most commonly used method for enteral feeding.^{1,2} It is not possible to place a PEG due to the absence of transillumination, which is commonly encountered in patients with large hiatal hernias or organ transposition.² Rarely, this procedure should be performed on patients with past histories of gastric surgery or gastrectomy. Previously, such procedures have been thought to be contraindicated for the PEG placement.^{3,4} However, the procedure could be completed without complications if there is adequate transillumination. Here, I would like to emphasize the importance of transillumination as a guide for placement site, even in patients who have had gastrectomies. Also, jejunum loops should be attempted for tube placement.

Two patients with cerebrovascular accidents and past histories of distal partial gastrectomies for ulcer disease were referred to the endoscopy unit for PEG tube placement. Both patients had midline incision scars and no transillumination was seen in their residual stomachs during routine upper gastrointestinal (GI) endoscopy. Both had Billroth II type gastrectomies with a small fundal pouch remaining. The endoscope was further advanced into the afferent and efferent loops to search for a possible insertion site, which was found in the efferent loop (Figure 1a). In both cases, the insertion site was almost 10 cm distal to the anastomosis site. In Figure 1b the finger indentation is clearly visible, 1 to 2 cm lateral left of the midline incision scar on the abdominal wall. The anesthesia infiltration needle (Figure 1c) and introducer (Figure 1d) are clearly seen. The procedure was completed uneventfully and a bumper was seen in position (Figure 1e). Both patients were followed for one year and had no complications related to

the procedure.

The PEG procedure can be difficult for patients with abdominal surgery, gastric resection, ascites, or obesity.³ Failed PEG procedures leave surgical gastrostomy or jejunostomy as possible alternatives, which are both expensive and carry a higher mortality and morbidity.⁵ Direct percutaneous endoscopic jejunostomy (DPEJ) is a relatively recent and evolving alternative to surgery. The success rate of DPEJ varies between 68% and 97.5%, probably due to technical differences.^{2,6} Fluoroscopy/ultrasound guidance may make the success rate higher. Moreover, the success rate is reported to be higher in patients with prior surgery (subtotal gastrectomy with Billroth II reconstruction or total gastrectomy) because the previous gastrojejunostomy facilitates jejunal access.^{5,6}

In conclusion, DPEJ should be attempted in all patients with altered gastric anatomy. Adhesions or scars due to abdominal surgery seem not to be a problem for procedural success. If the transillumination or finger indentation is clearly visible, there is a high possibility to complete the DPEJ procedure.

References

- Freeman C, Delegge MH. Small bowel endoscopic enteral access. *Curr Opin Gastroenterol.* 2009; **25**: 155 – 159.
- Moran GW, Fisher NC. Direct percutaneous endoscopic jejunostomy: High completion rates with selective use of a long drainage access needle. *Diagn Ther Endosc.* 2009; doi:10.1155/2009/520879
- Selim NM. Endoscopic identification of the jejunum facilitates minimally invasive jejunostomy tube insertion in selected cases. *Surg Endosc.* 2009; **23**: 2587 – 2590.
- Jabbar A, McClain CJ, McClave S. Chapter 32. Percutaneous endoscopic gastrostomy. In: Bayless TM, Diehl AM. *Advanced Therapy in Gastroenterology and Liver Disease.* 5th ed. Ontario: B.C. Decker; 2005: 196 – 201.
- Del Piano M, Ballaré M, Carmagnola S, Orsello M, Garello E, Pagliarulo M, et al. DPEJ placement in cases of PEG insertion failure. *Dig Liver Dis.* 2008; **40**: 30 – 35.
- Maple JT, Petersen BT, Baron TH, Gostout CJ, Wong Kee Song LM. Direct percutaneous jejunostomy: Outcomes in 307 consecutive attempts. *Am J Gastroenterol.* 2005; **100**: 2681 – 2688.

Authors' affiliations: ¹Hacettepe University School of Medicine, Department of Gastroenterology

Corresponding author and reprints: Taylan Kav MD, Hacettepe University School of Medicine, Department of Gastroenterology, Ankara, Turkey, 06100, E-mail: tkav@hacettepe.edu.tr

Accepted for publication: 19 October 2011