

Photoclinic

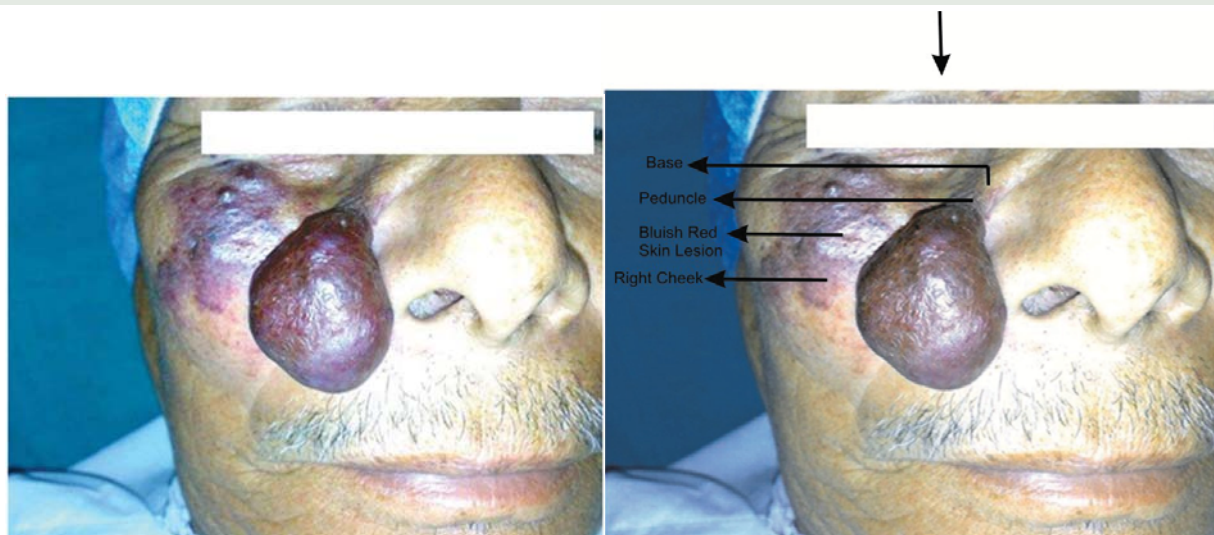

Figure 1. A single pedunculated, non-pulsatile, bluish red mass was originating from the upper 1/3 of the right nasolabial fold and extending up to the right side of upper lip.

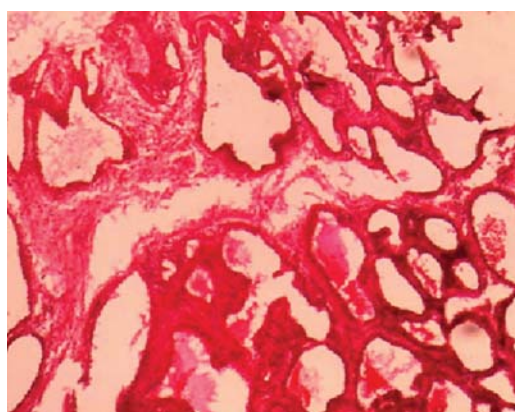


Figure 2. Histopathology showed interconnecting congested endothelium lined vascular channels, deposition of perivascular fibrous tissue, and multilaminated basement membranes (Hematoxylin and Eosin Stain, 100x).

A 76-year-old male presented to the Outpatient Department of General Surgery at Sikkim Manipal Institute of Medical Sciences with complaints of a pedunculated mass on his right cheek since seven years. The base of the peduncle was surrounded by a bluish red skin lesion, present since 30 years. There was a disproportionate growth of the skin lesion, particularly at the upper one third of the right nasolabial fold since seven years that gradually assumed a pedunculated shape. He denied the lesion being present since birth. Medical history included involution with infection of some areas of the skin lesion in the past. The patient denied having any significant medical problems or any significant allergic history. He was not on any medications. Family history disclosed no similar lesion in the family tree and he belonged to a middle class family.

Kincho Lhasong Bhutia MS¹

Author's affiliation: Department of General Surgery, Sikkim Manipal Institute of Medical Sciences, Sikkim, India.

Corresponding author and reprints: Kincho Lhasong Bhutia MS, Near Modern School, Upper Tathangchen, P.O. Raj Bhawan, Gangtok, 737101 Sikkim, India. Tel: +91-943-411-7461, E-mail: kllhasong@gmail.com

Accepted for publication: 8 March 2011

On physical examination, he was well nourished, oral temperature was 98.6°F (37.0°C), blood pressure was 140/70 mmHg, pulse regular with a rate of 70 beats per minute, and respiratory rate of 22 per minute. Systemic examination was within normal limits. A complete body examination revealed no similar lesion or the presence of any other skin lesion. Peripheral arterial pulses of both the upper and lower limbs were within normal limits.

On local examination (Figure 1 and 2), the pedunculated mass was noted to originate from the upper one third of the right nasolabial fold with extension to the right side of the upper lip. This was a single mass, bluish red in color, globular in shape, the translumination was bluish red and auscultation revealed no bruits. The swelling was nontender and nonpulsatile.

All the routine laboratory investigations were within normal limits. Finally, a histopathological examination confirmed the diagnosis.

**What is your diagnosis?
See the next page for diagnosis.**

Photoclinic Diagnosis:

Pedunculated Facial Hemangioma in An Adult.

The term hemangioma refers to the common angiomatous tumor of infancy that exhibits rapid postnatal growth and slow regression during childhood. The history did not reveal any congenital or acquired etiological factors. The patient had no symptoms other than mild local discomfort and obvious cosmetic disfigurement.

Approximately 80% of hemangiomas grow as a single tumor¹ and 20% proliferate in multiple sites. Hemangiomas are more common in females with a female to male ratio of 3 – 5:1. The incidence in Caucasian infants is 10 – 12% and is 22% in preterm infants who weigh less than 1000 gm. The incidence is lower in infants with darker skin. Prenatal associations include older maternal age, placenta previa and pre-eclampsia.² Basic fibroblast growth factor (bFGF) and vascular endothelial growth factor (VEGF) messenger RNA's are upregulated in proliferative hemangiomas.^{3,4} VEGF is localized predominantly in pericytes and endothelial cells during the proliferative phase. bFGF is found in endothelial cells in both the proliferative and early involutional phases. Other studies indicate that the angiogenic peptide, bFGF, is elevated in the urine of infants with proliferating hemangiomas.¹

Hemangiomas appear in the neonate, usually within the first two weeks of life. Deep subcutaneous or visceral hemangiomas may not manifest until two to three months of life. Approximately 30% to 40% of hemangiomas are nascent at birth, presenting as a premonitory cutaneous mark. The lesions are composed of proliferating blood vessels and although benign, have a potentially destructive character. Hemangiomas undergo a proliferative and an involution stage. Congenital hemangioma is a rare variant that grows in utero and presents completely formed at birth.⁵ They do not proliferate. Sometimes the infant presents with neonatal hemangiomatosis, which refers to an infant with multiple cutaneous hemangiomas. Such patients may have intrahepatic hemangiomas that can cause congestive heart failure, hepatomegaly and anemia. Hemangiomas may be associated with other underlying conditions; lumbosacral hemangiomas may be overlying an occult spinal dysraphism as a tethered cord, lipomenigocele and diastematomyelia. PHACES syndrome is the association of the following: P, Dandy–Walker or other cystic malformations in the posterior cranial fossa; H, large facial hemangioma; A, arterial abnormalities; C, cardiac defects; E, eye anomalies; and S, sternal cleft. Subglottic hemangioma should be suspected in an infant with a facial hemangioma who presents with dyspnea and stridor. Diffuse hemangioma of the perineum and the lower limb is also seen with urogenital and anorectal anomalies.

The differential diagnosis includes deep lymphatic or venous vascular malformations.⁶ The presence of the lesion at birth supports the diagnosis of a vascular malformation although congenital hemangiomas are observed at birth.⁵ Pyogenic granuloma is also confused with hemangioma. These typically arise in the central face, they are small (average diameter: 6.5 mm) and rarely appear before six months of age (mean age: 6.7 years). Pyogenic granulomas grow rapidly, erupt through the skin and form a stalk

or pedicle. Epidermal breakdown and crusting are common along with recurrent bleeding. Other differential diagnoses include: kaposiform hemangioendothelioma, tufted angioma, myofibromatosis, and fibrosarcoma.

Ultrasonography or magnetic resonance imaging (MRI) can confirm the diagnosis when in doubt.⁷ The patient underwent surgical excision under local anesthesia. An elliptical incision was made around the base of the pedicle. The feeding vessel was transfixed, the mass excised and the skin was repaired by interrupted sutures. He was followed up at one month and then one year with no additional complaints.

Additionally, a number of other therapies,⁸ depending on individual cases are as follows: observation, local wound care, local pressure, local or systemic steroids, recombinant interferon alfa-2a, flash lamp pulsed dye laser, intralesional laser [using potassium-titanyl-phosphate (KTP) alone or in combination with Nd:YAG lasers], and carbon dioxide laser in addition to superselective catheterization and embolization.

Funding/support source acknowledgement
None

Presentation details regarding the articles – presentations venue and awards, if any:

None

Acknowledgments

The present manuscript has been possible with the support given by my beloved wife, Lhamu and daughter, Kesangla.

References

1. Mulliken JB. Vascular Anomalies. In : Thorne CH, eds. *Grabb and Smith's Plastic Surgery*. 6th ed. New York: Lippincott Williams and Wilkins; 2006.
2. Haggstrom AN, Drolet BA, Baselga E, Chamlin SL, Garzon MC, et al. Hemangioma Investigator Group. Prospective study of infantile hemangiomas: demographic, prenatal, and perinatal characteristics. *J Pediatr*. 2007; **150**: 291 – 294.
3. Takahashi K, Mulliken JB, Kozakewich HP, Rogers RA, Folkman J, Ezekowitz RA. Cellular markers that distinguish the phases of hemangioma during infancy and childhood. *J Clin Invest*. 1994; **93**: 2357 – 2364.
4. Chang J, Most D, Bresnick S, Mehrara B, Steinbrech DS, Reinisch J, et al. Proliferative hemangiomas: analysis of cytokine gene expression and angiogenesis. *Plast Reconstr Surg*. 1999; **103**: 1 – 9.
5. Boon LM, Enjolras O, Mulliken JB. Congenital hemangioma: evidence of accelerated involution. *J Pediatr*. 1996; **128**: 329 – 335.
6. Mulliken JB, Glowacki J. Hemangiomas and vascular malformations in infants and children: A classification based on endothelial characteristics. *Plast Reconstr Surg*. 1982; **69**: 412 – 422.
7. Armstrong DC, ter Brugge K. Selected interventional procedures for pediatric head and neck vascular lesions. *Neuroimaging Clin N Am*. 2000; **10**: 271 – 292.
8. Marler JJ, Mulliken JB. Current management of hemangiomas and vascular malformations. *Clin Plastic Surg*. 2005; **32**: 99 – 116.