

## Case Report

# Intraparenchymal Leiomyoma of the Breast

Miroslav Granic MD PhD<sup>1,5</sup>, Magdalena Stefanovic-Radovic MD<sup>2</sup>, Darko Zdravkovic MD<sup>1,5</sup>, Nebojsa Ivanovic MD<sup>1,5</sup>, Dejan Nikolic MD<sup>1,5</sup>, Dragan Radovanovic MD<sup>3,5</sup>, Miodrag Stojiljkovic MD<sup>4</sup>

## Abstract

The most common location of the leiomyoma is uterus, small bowel and the esophagus, however they can occur in any organ. Intraparenchymal leiomyomas of the breast are very rare and only 30 cases were reported in the literature. These histologically benign tumors, may mimic malignancies and therefore may present a diagnostic challenge. Here, we present two new cases. The first case was a 50-year-old woman presented with a 4 cm firm mass in her right breast with discrete localized skin thickening/retraction. The second case was a 35-year-old woman presented with a painless palpable lump in the lower outer quadrant of her right breast. Physical examination, mammography and ultrasound as well as surgical excision were performed in both cases. According to histologic examination and immunohistochemical analysis, a diagnosis of smooth muscle tumor of the breast was made. These tumors clinically and radiologically mimic other breast lesions. Neither imaging studies nor palpation allow distinction between benign and malignant tumors.

**Keywords:** Benign tumor, breast neoplasms, leiomyoma

**Cite this article as:** Granic M, Stefanovic-Radovic M, Zdravkovic D, Ivanovic N, Nikolic D, Radovanovic D, Stojiljkovic M. Intraparenchymal leiomyoma of the breast. *Arch Iran Med.* 2015; **18**(9): 608 – 612.

## Introduction

Leiomyoma is a benign smooth muscle neoplasm. The most common location for leiomyoma, is in uterus, small bowel and the esophagus. They can develop with unusual growth patterns or in several atypical locations that make their identification more challenging, both clinically and radiologically. Although they are histologically benign, may mimic malignant tumors, and may present a diagnostic challenge.

Intraparenchymal leiomyomas of the breast are described only in women and the fact that they are extremely rare is shown by only 30 cases reported in the literature.<sup>1-30</sup> Here, we report two cases of parenchymal leiomyoma of the breast that were recognized in one year with the description of the clinical, radiologic, histopathologic, and immunohistochemical findings. Here, two mutually different types of leiomyomas of the breast, according to patients' clinical and imaging characteristics have been presented.

## Case Report

### Case 1

A 50-year old woman presented with a palpable painless right breast mass. The patient was obese, and premenopausal. She was not on hormone therapy, and had uterine myoma. She had her menarche at 13 year of age, first full-term pregnancy at age 24 and was breastfed for 9 months. She had primary hypothyroidism, regulated by substitution therapy. She had a functional inactive mass of the right suprarenal gland discovered 13 years ago by

routine abdominal ultrasound, confirmed by abdominal computed tomography (CT) and magnetic resonance (MR) examination.

There was no family history of Breast cancer (BC) and any prior breast diseases or examinations. Physical examination revealed a 4 cm firm immobile mass in the RLI (right low inner lower) quadrant and discrete localized skin thickening/retraction. Axillary lymph nodes were enlarged. The mammography showed scattered fibroglandular densities (ACR 2) and revealed 4.5 cm oval, dense mass with indistinct margins, which was located deep in the low inner quadrant of the right breast, without microcalcifications or spicules. The mass was assessed as a BIRADS 4 category (Figure 1). Ultrasonography (US) of the right breast showed 4 cm oval hypoechoic homogenous mass without cystic features, with lobulated borders, hyperechoic rim and posterior shadowing. Surgical excision was performed. A 4 cm × 4 cm × 3 cm well circumscribed, rubbery, white mass with white whorled cut surface was noted on gross examination. Lymph nodes showed the presence of only reactive changes. Histologic examination of the surgical specimen identified the mass consisted of interlacing fascicles of spindle-shaped cells with abundant eosinophilic cytoplasm and indistinct cell borders. The uniform nuclei of the spindle-shaped cells were ovoid with blunt ends, delicate chromatin and occasional small nucleoli. No cytologic atypia or necrosis was seen. Mitotic figures were rare (2/50 high-power fields (HPF)). The tumor showed a low Ki-67 proliferation index (5% of the tumor cells showed proliferative activity). Immunohistochemical stains showed diffuse strong positivity for desmin and smooth muscle actin (Figure 2). Immunohistochemical stains for CD 34, S100protein, AE1/AE3 cytokeratin and p63 were negative. A diagnosis of intraparenchymal leiomyoma was made.

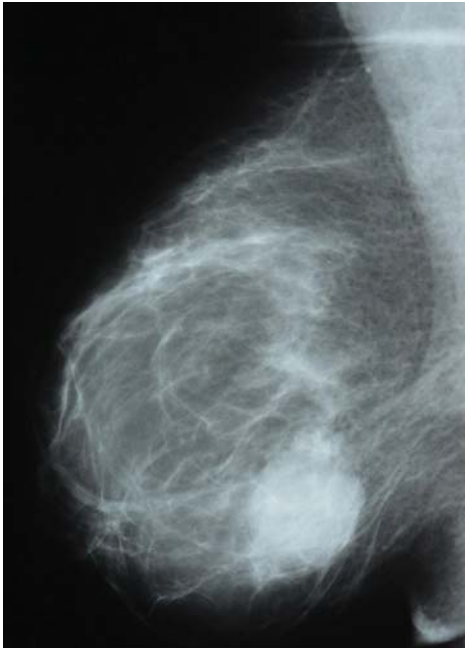### Case 2

A 35-year old woman presented with a painless palpable lump in the lower outer quadrant of the right breast. She was premenopausal, nulliparous woman and had her menarche at 13 year of age. The patient was in good health, had no family history of BC

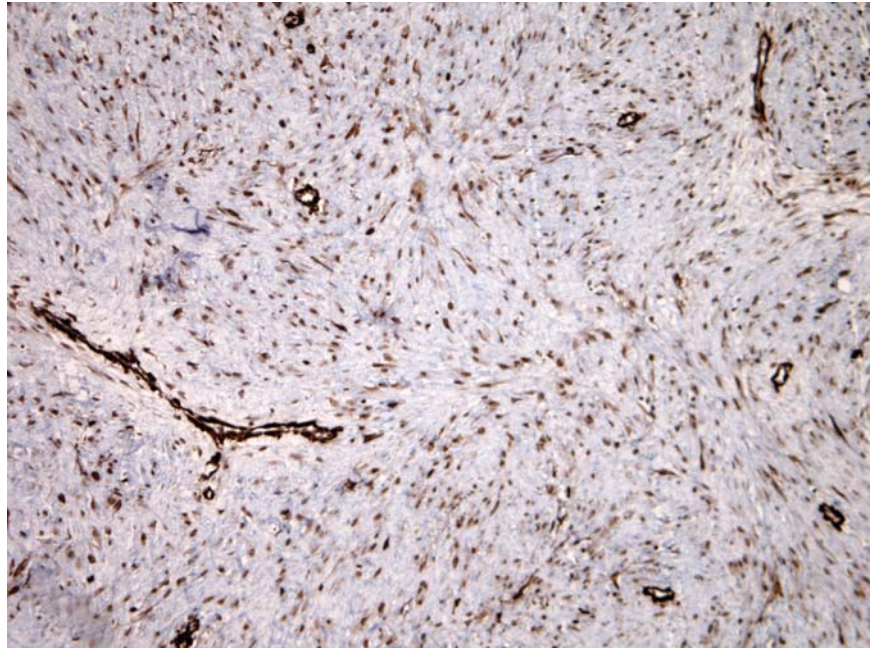
**Authors' affiliations:** <sup>1</sup>Department of Surgical Oncology, University Medical Center "Bezanijska kosa", Belgrade, Serbia, <sup>2</sup>Department of Radiology, University Medical Center "Bezanijska kosa", Serbia, <sup>3</sup>Department of Thoracic Surgery, University Medical Center "Bezanijska kosa", Serbia, <sup>4</sup>Department of Pathology, University Medical Center "Bezanijska kosa", Serbia, <sup>5</sup>Faculty of Medicine, University of Belgrade, Serbia.

**Corresponding author and reprints:** Miroslav Granic MD PhD, University Medical Center Bezanijska kosa, Autoput bb, 11000 Belgrade, Serbia. Tel: +38-1113010777, Fax: +38-1112606520, E-mail: granic@bkosa.edu.rs.

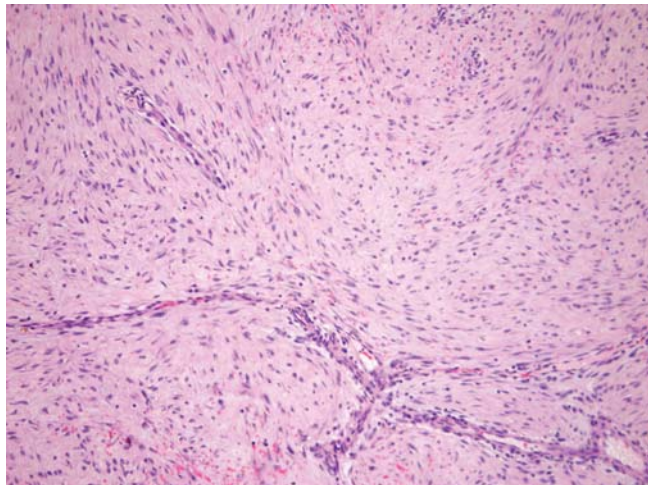
Accepted for publication: 24 March 2015



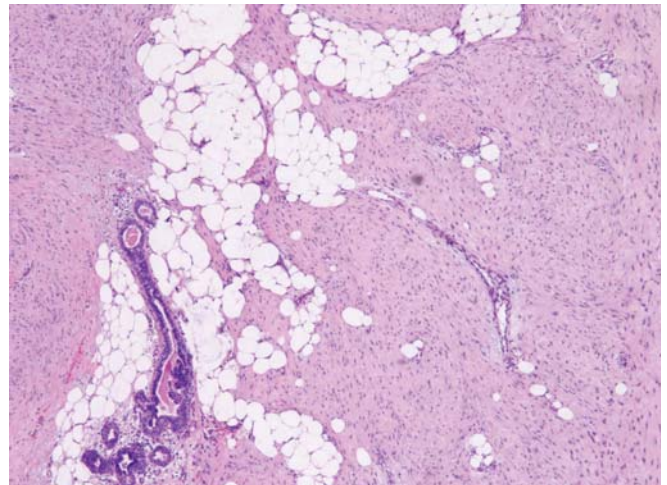
**Figure 1.** Mammography of the right breast- MLO projection



**Figure 2.** SMA-Immunohistochemical staining for smooth muscle actin shows diffuse strong cytoplasmic positivity (H&E, 400x)



**Figure 3.** HE-Histologic section of the core needle biopsy shows interlacing fascicles of spindle shaped cells (H&E, 200x).



**Figure 4.** HE-Histologic section of the core needle biopsy shows interlacing fascicles of spindle shaped cells (H&E, 200x).

and was not on hormone therapy. Preoperative physical examination revealed a 2 cm firm, well-circumscribed, mobile, oval mass in the right breast. There were no skin changes, nipple discharge or axillary lymphadenopathy. The patient was referred to US examination 6 years ago, after she revealed a palpable mass in her right breast. The first sonography of the right breast showed well-marginated, oval, slightly lobulated mass measured 10 mm × 6 mm that was iso to hyperechoic compared with breast parenchyma, with no evidence of posterior enhancement. The lesion was interpreted as a fibroadenoma. She had undergone breast sonography annually for four years. The measure of the lesion were 16.3 mm × 8.2 mm on sonography.

The patient preferred further US follow up other than suggested surgical excision. The mass had been enlarged (20 mm) considerably and there were no changes in imaging features six years later. Although, the mammography revealed an extremely dense tissue composition (ACR 4) and oval, well-circumscribed dense lesion measured 20 mm × 15 mm in the right breast, the mammography

showed no calcification. The patient underwent surgical excision.

On gross examination, a 3 cm × 2 cm × 2 cm well circumscribed, rubbery, white mass with white whorled cut surface was noted with adequate surgical margins. Histologic examination of the surgical specimen identified the mass consisted of interlacing fascicles of spindle-shaped cells with abundant eosinophilic cytoplasm and indistinct cell borders. The uniform nuclei of the spindle-shaped cells were ovoid with blunt ends, delicate chromatin and occasional small nucleoli. No cytologic atypia or necrosis was seen. Mitotic figures were rare (1/50 HPF). Immunohistochemical stains showed diffuse strong positivity for desmin and smooth muscle actin. Immunohistochemical stains for AE1/AE3 cytokeratin were negative (Figure 3 and 4). A diagnosis of intraparenchymal leiomyoma was made.

## Discussion

Leiomyoma of the breast belong to the heterogeneous group of

breast spindle cell tumors (BSCT), which are quite rare.<sup>23</sup>

Since their initial description by Strong,<sup>3</sup> there were only 30 cases of leiomyoma that have been reported in the literature to date.<sup>1-30</sup> Our cases represent the 31<sup>st</sup> and 32<sup>nd</sup> reports of leiomyoma of the breast, with completely different clinical and imaging features, one mimicking carcinoma, and the other fibroadenoma. Both cases underwent surgical excision and confirmed the same histopathologic and immunohistochemical diagnosis -leiomyoma.

Leiomyoma of the breast is a rare benign nonepithelial tumor. When leiomyoma occur in the breast, due to the abundance of smooth muscle cells around the nipple and areola,<sup>2</sup> they are most commonly seen in the subareolar region and have been reported in both sexes.<sup>1</sup>

There are two types of breast leiomyomas, depending on the tissue origin, such as superficial (from dermal smooth muscle) and vascular (from vascular endothelium). Superficial leiomyomas are located in the skin and subcutaneous tissues and involve nipple or areolar region, while vascular leiomyomas are located deeper within the breast parenchyma and are less common than the superficial leiomyomas.<sup>23</sup> The histogenesis of these tumors is still controversial and unknown, although there are various theories trying to explain the origin of these neoplasms. One theory proposed that they develop from smooth muscle cells that surround capillaries in the subcutaneous breast tissues. There is also

the other theory concerning the origin of these neoplasms, suggested by Diaz-Arias, et al. which proposed 5 sources: proliferation of smooth muscle cells surrounding blood vessels, teratoid origin with the extreme overgrowth of myomatous elements, differentiation of multipotent mesenchymal cells in breast tissue, and derivation from myoepithelial cells of breast ducts with clear differentiation to smooth muscle, or embryologically displaced smooth muscle cells from the nipple.<sup>11,21,24</sup> Patients' characteristics are summarized in Table 1.

Analyzing symptoms and clinical appearance, except a clinically palpable painless lump, patients mostly complained of discomfort and pain. Only two cases were reported skin changes and one of them is our case. Tumor size varied from 0.5 to 13.8 cm and most of them were well-circumscribed. Cases reported after 1947, were treated by segmental excision<sup>8-30</sup> with no recurrence. Boscaino, et al.<sup>32</sup> reported two cases initially diagnosed as a leiomyomas, that developed local recurrence after 3 and 4 years. They were retrospectively analyzed and revealed a higher mitotic activity thus suggesting assigning those cases to a borderline class between leiomyomas and leiomyosarcomas.

On mammography, the majority of reported leiomyomas are well marginated, homogenous and dense (moderately or highly).<sup>15,22</sup> There were no evidence of microcalcification, architectural distortion, skin thickening or nipple retraction.

**Table 1.** Clinical findings in 32 reported cases of intraparenchymal leiomyoma of the breast

Case No	Ref	Gender	Age	Location	Size (cm)	Symptom	Treatment
1	3	F	46	RUO	6.0	Discomfort	NR
2	4	F	34	RUO	3.0	Discomfort	Excision
3	5	F	45	RLC	3.0	Pain	Simple mastectomy
4	6	F	58	C	13.8	Discomfort	Simple mastectomy
5	7	F	54	RUI	4.0	Discomfort	Radical mastectomy
6	8	F	40	LLO	10.0	Pain	Excision
7	9	F	50	RUO	0.5	Tenderness	Excision
8	10	F	52	C	2.5	None	Excision
9	10	F	40	LUO	3.0	None	Excision
10	11	F	69	RUO	2.5	None	Excision
11	12	F	43	LU	2.5	None	Excision
12	13	F	42	RUI	0.7	None	Excision
13	14	F	42	RUO	4.5	None	Excision
14	15	F	42	LUI	3.5	None	Excision
15	16	F	53	LUI	10.0	Enlargement	Excision
16	17	F	54	RUC	5.5	None	Excision
17	18	F	50	RUO	1.0	Dull pain	Excision
18	19	F	48	LUO	4.0	Self palpation	Excision
19	20	F	45	LUI	1.6	Tenderness	Excision
20	21	F	47	LCI	2.7	Enlargement	Excision
21	22	F	47	RUI	1.5	Noticed a mass	Excision
22	23	F	39	DEEP	4.0	NR	Excision
23	24	F	48	LUI	1.0	None	Excision
24	25	F	34	LUO	5.0	Painless mass	Excision
25	26	F	52	RUO	5.0	Breast lump	Excision
26	27	F	63	RUC	1.7	None	Excision
27	28	F	53	C	0.5	None	Excision
28	29	F	36	R	2.0	None	Excision
29	30	F	27	LUI	2.0	None	Excision
30	31	M	70	LUO	7.0	None	Excision
31	Present case,1 <sup>st</sup>	F	50	RLI	4.0	Noticed a mass	Excision
32	Present case,2 <sup>nd</sup>	F	35	RLO	2.0	Enlargement	Excision

M: male; F: female; R: right; L: left; I: inner; O: outer; C: central; U: upper; L: lower; NR: non reported.

According to sonography results, these lesions are mainly solid, well circumscribed and homogenous, possibly containing semi-cystic components. Posterior echoes may be lacking, enhanced and rarely decreased.<sup>22,27</sup>

MR imaging was used in only one case of leiomyoma of the breast<sup>27</sup> and described precise assessment of the number, size and location of this lesion. MR imaging features of parenchymal leiomyoma of the breast is typical for smooth muscle tumors. The type of degeneration and distinction between benign and malignant tumor degeneration cannot be precisely done by MR.<sup>33</sup>

The 2<sup>nd</sup> case had typical mammographic and sonographic appearance of leiomyoma of the breast. There was well circumscribed, highly dense lesion on mammography, and hyperechoic, well defined, with the absence of posterior enhancement on sonography. Therefore, the tumor was difficult to differentiate from an atypical fibroadenoma,<sup>18</sup> but the enlargement was the feature that suggested lesion other than fibroadenoma preoperatively and suggested excision.<sup>21</sup>

The first case had imaging features of carcinoma according to mammographic and sonographic findings.

But, the histologic and immunohistochemical findings in our cases are typical.

Microscopically, they present like leiomyomas in other sites. There is no nuclear atypia, hypercellularity, a high rate of mitosis or necrosis. On immunoperoxidase staining, most leiomyomas are positive for vimentin, desmin, and muscle specific actin. However, S-100 and cytokeratin stains were negative.<sup>11</sup>

Differentiating benign intraparenchymal leiomyoma from other breast lesions is essential to determining proper treatment.

The histopathological differential diagnoses for leiomyoma of the breast include leiomyosarcoma, the spindle cell variant of adenomyoepithelioma, myofibroblastoma, fibromatosis, benign nerve sheath tumors including neurofibromas, and benign, as well as malignant phyllodes tumors.<sup>11,23,24</sup> The most important differential diagnosis is leiomyosarcoma of the breast.<sup>11</sup> The most important differential diagnosis is with leiomyosarcoma.<sup>34</sup> Leiomyosarcomas of the breast are similar to intraparenchymal leiomyomas, since the typical mammographic appearance of these tumors are dense, well circumscribed non invasive lesion and they present many years prior to diagnosis.<sup>34</sup> The importance of differentiating these tumors is because breast leiomyosarcomas have the potential of local recurrence or distant metastasis which occur via hematogenous spread many years after excision.<sup>35</sup> Histologically, leiomyosarcomas feature prominent cytologic atypia, with 2 – 16 mitotic figures per 10 high-power fields, atypical mitoses, vascular invasion, and necrosis.<sup>36</sup>

In our cases leiomyosarcoma was excluded because of an absence of mitosis, necrosis and cellular atypia. The treatment for intraparenchymal leiomyoma of the breast is simple excision. There has been no evidence of a distant spread or transformation to a malignant form of smooth muscle tumor.

In conclusion, intraparenchymal leiomyoma of the breast is an extremely rare tumor that can clinically and radiologically mimics other breast lesions. Neither imaging studies nor palpation allow distinction between benign and malignant tumors. Therefore, after recommended simple excision with free margins, thorough histological examination is essential for a proper diagnosis.

## References

1. Tsujioka K, Kashihara M, Imamura S. Cutaneous leiomyoma of the male nipple. *Dermatologica*. 1985; **170**: 98 – 100.
2. Kaufman HL, Hirsch EF. Leiomyoma of the breast. *J Surg Oncol*. 1996; **62**: 62 – 64.
3. Strong LW. Leiomyoma of the breast. *Am J Obstet*. 1913; **68**: 53 – 55.
4. Schauder H. Uber leiomyome der brustdruse. *Deutsch Z Chir*. 1927; **205**: 58 – 68.
5. Melnick PJ. Fibromyoma of the breast. *Arch Pathol*. 1932; **14**: 794 – 798.
6. Lebowich RJ, Lenz G. Primary fibromyoma of the breast. *Am J Cancer*. 1940; **38**: 73 – 75.
7. Stein RJ. Fibroleiomyoma of the breast. *Arch Pathol*. 1942; **33**: 72 – 74.
8. Craig JM. Leiomyoma of the female breast. *Arch Pathol*. 1947; **44**: 314 – 317.
9. Libcke JH. Leiomyoma of the breast. *J Pathol*. 1969; **98**: 89 – 90.
10. Haagensen CD. Nonepithelial neoplasms of the breast. In: Haagensen CD, editor. *Diseases of the breast*. 2nd ed. Philadelphia: WB Saunders Co. 1971; p. 297 – 299.
11. Diaz-Arias AA, Hurt MA, Loy TS, Seeger RM, Bickel JT. Leiomyoma of the breast. *Hum Pathol*. 1989; **20**: 396 – 399.
12. Lauwers G, De Roux S, Terzakis J. Leiomyoma of the breast. *Arch Anat Cytol Pathol*. 1990; **38**: 108 – 110.
13. Manna P, Giuseppetti GM, Latini L, Baldassarre S, Antognoli S. A case of leiomyoma of the breast. *Radiol Med*. 1993; **86**: 155 – 158.
14. Roncaroli F, Rossi R, Severi B, Martinelli GN, Eusebi V. Epithelioid leiomyoma of the breast with granular cell change: a case report. *Hum Pathol*. 1993; **24**: 1260 – 1263.
15. Tamir G, Yampolsky I, Sandbank J. Parenchymal leiomyoma of the breast. Report of a case and clinicopathological review. *Eur J Surg Oncol*. 1995; **21**: 88 – 89.
16. Nazario AC, Tanaka CI, de Lima GR, Gebrim LH, Kemp C. Leiomyoma of the breast. A case report. *Sao Paulo Med J*. 1995; **113**: 992 – 994.
17. Weldon C, Jones B, Daroca P, Beech D. Breast leiomyoma. *J La State Med Soc*. 1998; **150**: 367 – 370.
18. Son EJ, Oh KK, Kim EK, Son HJ, Jung WH, Lee HD. Leiomyoma of the breast in a 50 – year – old woman receiving tamoxifen. *Am J Roentgenol*. 1998; **171**: 1684 – 1686.
19. Sidoni A, Luthy L, Bellezza G, Consiglio MA, Bucciarelli E. Leiomyoma of the breast: case report and review of the literature. *Breast*. 1999; **8**: 289 – 290.
20. Kotsuma Y, Wakasa K, Yayoi E, Kishibuchi M, Kishibuchi M, Sakamoto G. A case of leiomyoma of the breast. *Breast Cancer*. 2001; **8**: 166 – 169.
21. Pourbagher A, Pourbagher MA, Bal N, Oguzkurt L, Ezer A. Leiomyoma of the breast parenchyma. *Am J Roentgenol*. 2005; **185**: 1595 – 1597.
22. Heyer H, Ohlinger R, Schimming A, Schwesinger C, Grunwald S. Parenchymal leiomyoma of the breast—clinical, sonographic, mammographic and histological features. *Ultraschall Med*. 2006; **27**: 55 – 58.
23. Abd El All HS. Breast spindle cell tumours: About eight cases. *Diagn Pathol*. 2006; **1**: 1 – 13.
24. Ende L, Mercado C, Axelrod D, Darvishian F, Levine P, Cangiarella J. Intraparenchymal leiomyoma of the breast: a case report and review of the literature. *Ann Clin Lab Sci*. 2007; **37**: 268 – 273.
25. Mandal S, Dhingra K, Khurana N. Parenchymal leiomyoma of breast, mimicking cystosarcoma phylloides. *ANZ J Surg*. 2008; **78**: 108 – 109.
26. Koirala K, Shrestha ML, Chalise PR, Shrestha BB, Shrestha R. Leiomyoma of breast: a report of rare case. *NMCJ*. 2008; **10**: 207 – 208.
27. Minami S, Matsuo S, Azuma T, Uga T, Hayashi T, Eguchi S, et al. Parenchymal leiomyoma of the breast: a case report with special reference to magnetic resonance imaging findings and an update review of literature. *Breast Cancer*. 2011; **18**: 231 – 236.
28. Wang H, Luo B, Li F. Nipple inversion caused by a breast leiomyoma. *Breast J*. 2012; **18**: 376 – 377.
29. Vecchio GM, Cavaliere A, Cartaginosa F, Lucaccioni A, Lombardi T, Parenti R, et al. Intraparenchymal leiomyoma of the breast: report of a case with emphasis on needle core biopsy – based diagnosis. *Pathologica*. 2013; **105**: 122 – 127.
30. Shah SD, Gupta A, Roy S, Mukhopadhyay S. Intraparenchymal leiomyoma of the breast: a case report. *Indian J Surg*. 2013; **75**: 88 – 89.

31. Strader LA, Galan K, Tenofsky PL. Intraparenchymal leiomyoma of the male breast. *Breast J.* 2013; **19**: 675 – 676.
32. Boscaino A, Ferrara G, Orabona P, Donofrio V, Staibano S, De Rosa G. Smooth muscle tumors of the breast: clinicopathologic features of two cases. *Tumori.* 1994; **80**: 241 – 245.
33. Hricak H, Tscholakoff D, Heinrichs L, Fisher MR, Doms GC, Reinhold C, et al. Uterine leiomyomas: correlation of MR, histopathologic findings, and symptoms. *Radiology.* 1986; **158**: 385 – 391.
34. Stafyla VK, Gauvin JM, Farley DR. A 53-year-old woman with a leiomyosarcoma of the breast. *Curr Surg.* 2004; **61**: 572 – 575.
35. Munitiz V, Rios A, Canovas J, Ferri B, Sola J, Canovas P, et al. Primitive leiomyosarcoma of the breast: case report and review of the literature. *Breast.* 2004; **13**: 72 – 76
36. Nielsen BB. Leiomyosarcoma of the breast with late dissemination. *Virchows Arch A Pathol Anat Histopathol.* 1984; **403**: 241 – 245.