

Case Report

Bilateral Cystoid Macular Edema Secondary to Paclitaxel Treatment

Yilmaz Tezcan MD¹, Mustafa Surmeli MD¹, Didem Tastekin MD², Mehmet Koc MD¹**Abstract**

Cystoid macular edema is rarely observed secondary to paclitaxel treatment. A 55-year-old female patient was applied five cures of paclitaxel and carboplatin chemotherapy after being diagnosed with metastatic ovarian cancer. The patient had a normal bilateral vision prior to the chemotherapy treatments. After the fifth cure, the patient complained of bilateral vision loss, which was more severe in the left eye. Ophthalmologic examination revealed that right eye vision was 4/10 blurred without glasses and 7/10 blurred with glasses, left eye vision was 1/10 blurred without glasses and 4/10 blurred with glasses. Pathology was not detected during the biomicroscopic examination. Fundus examination of the patient revealed pigment epithelium irregularity, which was found to be less in the right eye, and it was found a decrease in foveal cavity. For fundus examination, the patient underwent fundus fluorescein angiography (FFA) and optical coherence tomography (OCT). FFA revealed fluorescein leakage and cystoid appearance particularly more apparent in the left eye. Thickening in the macula and cystoid space was observed particularly more in the left eye in the OCT measurement. In conclusion, we presented our case as a rarely observed cystoid macular edema secondary to paclitaxel treatment.

Keywords: Chemotherapy, cystoid macular edema, ovarian cancer, paclitaxel

Cite this article as: Tezcan Y, Surmeli M, Tastekin D, Koc M. Bilateral cystoid macular edema secondary to paclitaxel treatment. *Arch Iran Med.* 2015; **18**(9): 606 – 607.

Introduction

The most common causes of cystoid macular edema (CME) can be listed as cataract surgery, laser applications, inflammatory eye diseases and diabetes.¹ The incidence of CME that developed after cataract surgery is 1% – 2%.² Radiation retinopathy that develops depending on radiotherapies applied to the head and neck region may also result in CME. Although, the occurrence mechanism of CME has not been fully understood, It is considered that the collapse of the normal blood-brain barrier. Typical CME looks like a classic petal in the fluorescein angiogram.³ According to previous studies, certain antineoplastic agents, particularly taxane group chemotherapeutics play a role in the etiology of CME.⁴ Paclitaxel is a chemotherapeutic agent that is commonly used in the treatment of malignant tumors such as ovarian cancer, breast cancers, head and neck cancers, as well as lung cancers. It can be used either alone or together with other chemotherapeutic agents. Its effect mechanism shows antineoplastic effect through microtubule inhibition and causes cell death. Several side effects were reported, including allergic reactions, fever, nausea-vomiting, loss of appetite, muscle cramps and pain, weakness, peripheral neuropathies, hair loss and changes in the blood picture. Vision loss due to macular edema is fairly rare and has been reported in the literature as a rare side effect.⁵ We presented a rare case, who had bilateral vision loss because of cystoid macular edema secondary to paclitaxel.

Case Report

A 55-year old postmenopausal female had no specifications in personal or family history. The examinations performed for stomach-ache complaints showed the existence of a cystic mass formation in the left ovary and an increase in CA 125 antigen. During the exploration for the mass in the ovary, generalized metastatic disease was observed in the abdomen. Biopsies were taken and the operation was ended. Following the pathologic evaluation, the case was diagnosed with metastatic ovarian cancer and given combined chemotherapy including paclitaxel 175 mg/m² (Taxol; Bristol-Meyers Squibb Co., New York, NY, USA) and carboplatin AUC = 5. The metastatic disease region was subjected to palliative external radiotherapy. The patient had normal bilateral vision before the chemotherapies. However, an ophthalmologic examination was requested due to the bilateral vision loss that occurred after 5 cycles of chemotherapy treatments. Ophthalmologic examination revealed that right eye vision was 4/10 blurred without glasses and 7/10 blurred with glasses, left eye vision was 1/10 blurred without glasses and 4/10 blurred with glasses. Pathology was not detected in the biomicroscopic examination. Eye pressure measurements of the patient were performed using a pneumotonometer and found as 15 mm in the right eye and 17 mm in the left eye. Fundus examination of the patient revealed pigment epithelium irregularity, which was found to be less in the right eye, and was found decrease in foveal cavity. For fundus examination, the patient underwent FFA and OCT. Left eye FFA revealed fluorescein leakage and cystoid appearance in the macular area (Figure 1A) and left eye OCT measurement revealed thickening in the macula and cystoid image, left eye OCT measurement revealed thickening in the macula and cystoid image (Figure 1B). Macular thickening and cystoid appearance were found to be less in the right eye OCT measurement (Figure 1C). Based on these findings, the decrease in the bilateral vision of the patient was accepted as CME that developed secondary to paclitaxel treatment. For this reason, paclitaxel treatment was suspended.

Authors' affiliations: ¹N. E. U., Department of Radiation Oncology, Meram Faculty of Medicine, Konya, Turkey, ²I. U., Department of Medical Oncology, Istanbul Faculty of Medicine, Istanbul, Turkey.

Corresponding author and reprints: Yilmaz Tezcan MD, N. E. U., Department of Radiation Oncology, Meram Faculty of Medicine, 42090, Konya, Turkey. Tel: +90-3322236852, Fax: +90-3322236181, E-mail: yilmaztezcan@yahoo.com.

Accepted for publication: 24 March 2015

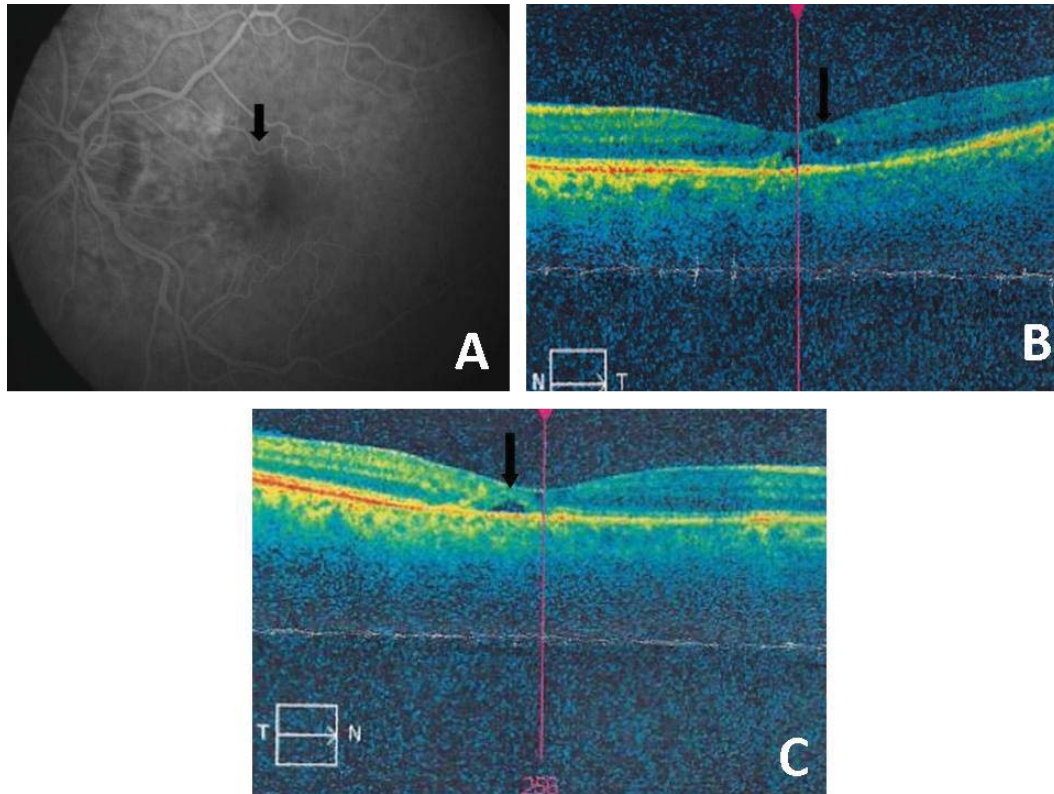


Figure 1. A) Left eye FFA revealed fluorescein leakage and cystoid appearance in the macular area. B) Left eye OCT measurement revealed thickening in the macula and cystoid image, which was more compared to right eye. C) Macular thickening and cystoid appearance were found to be less in the right eye OCT measurement.

Discussion

Patients who develop CME most frequently show vision loss symptoms. CME was observed due to intracellular fluid accumulation that caused toxicity in Müller. Similarly, the cystoid macular edema formation mechanism of paclitaxel was observed intracellular fluid accumulation and mild leakage of extracellular fluid due to toxicity in Müller cells. As a result, vision loss is observed in the patient depending on this mechanism. Suspending paclitaxel treatment is also suggested alongside medical treatments such as methazolamide. The location of the primary tumor, radiation explosion or the areas subjected to radiotherapy and the chemotherapeutic drugs should be examined in detail in patients with vision loss, particularly in cancer patients. Detailed ophthalmologic examinations of the patients must be performed and it is necessary to conduct the treatment through a multidisciplinary approach together with an ophthalmologist in patients using paclitaxel. Furthermore, about these side effects are uncommon in patients treated with paclitaxel should be very careful.

Conflict of Interest

The authors have no conflict of interest.

References

1. Tranos PG, Wickremasinghe SS, Stangos NT, Topouzis F, Tsinopoulos I, Pavesio CE. Macular edema. *Surv Ophthalmol.* 2004; **49(5)**: 470 – 490.
2. Ray S, D'Amico DJ. Pseudophakic cystoid macular edema. *Semin Ophthalmol.* 2002; **17**: 167 – 180.
3. Meyer KM, Klink T, Ugurel S, Bröcker EB. Regression of paclitaxel-induced maculopathy with oral acetazolamide. *Graefes Arch Clin Exp Ophthalmol.* 2012; **250(3)**: 463 – 464.
4. Smith SV, Benz MS, Brown DM. Cystoid macular edema secondary to albumin-bound paclitaxel therapy. *Arch Ophthalmol.* 2008; **126**: 1605 – 1616.
5. Murphy CG, Walsh JB, Hudis CA, Lake D, Theodoulou M. Cystoid macular edema secondary to nab-paclitaxel therapy. *J Clin Oncol.* 2010; **28(33)**: 684 – 687.